

Image Correspondence

Bedside Demonstration of Fluorescence Using 365 nm Wood's Lamp Mode of Dermoscope in Pityriasis Versicolor

Shrinivas Patil¹, Anuj Bhatnagar¹, Debdeep Mitra¹

¹Department of Dermatology, Venereology and Leprosy, Command Hospital Air Force Bengaluru, Bengaluru, Karnataka, India.

*Corresponding author:

Shrinivas Patil,
Department of Dermatology,
Venereology and Leprosy,
Command Hospital Air
Force Bengaluru, Bengaluru,
Karnataka, India.

shrinivas93doctor@gmail.com

Received: 29 March 2024
Accepted: 05 May 2024
Epub Ahead of Print: 03 June 2024
Published: 23 August 2024

DOI
10.25259/IJPGD_46_2024

Quick Response Code:



Pityriasis versicolor, although clinical diagnosis is usually made by the presence of hypo or hyperpigmented scaly macules [Figure 1], can sometimes present with atypical features, necessitating additional diagnostic modalities. Wood's lamp examination, particularly in the fluorescence can aid in the rapid diagnosis of this condition by highlighting the characteristic yellow-green fluorescence of the causative organism, *Malassezia* spp.

Dermoscopy, with its ability to magnify and visualise subtle skin changes, further enhances the diagnostic accuracy of Wood's lamp examination, especially at the bedside. Bedside demonstration of fluorescence using the 365 nm Wood's lamp mode of dermoscopy [Figure 2] is a valuable tool in the diagnosis of pityriasis versicolor, offering a rapid and non-invasive means of confirming the clinical suspicion. The green-yellow fluorescence observed in pityriasis versicolor lesions under Wood's light

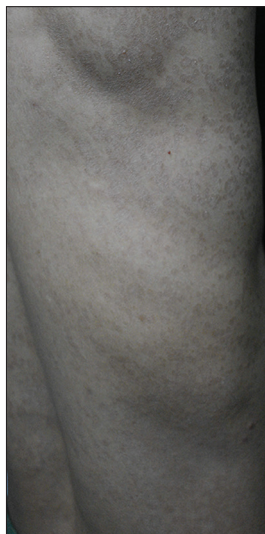

Figure 1: Multiple discrete to coalescing hyperpigmented brownish scaly macules distributed over the right side of trunk.

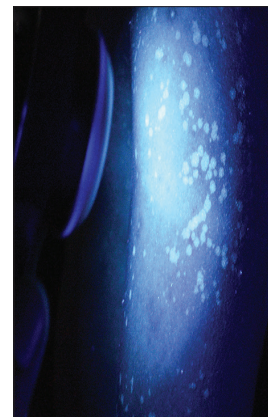


Figure 2: Demonstration of fluorescence using non-contact dermoscopy (DERMLITE DL5, 365 nm Woods lamp mode) showing yellow-green fluorescence.

This is an open-access article distributed under the terms of the Creative Commons Attribution-Non Commercial-Share Alike 4.0 License, which allows others to remix, transform, and build upon the work non-commercially, as long as the author is credited and the new creations are licensed under the identical terms.

©2024 Published by Scientific Scholar on behalf of Indian Journal of Postgraduate Dermatology



Figure 3: Contact dermoscopy (DERMLITE DL5, 365 nm woods lamp mode, ×10) showing yellow-green fluorescence.



Figure 4: Photograph showing green-yellow fluorescence as seen through woods lamp magnifier.

is attributed to the presence of pityrialactone [Figure 3]. Figure 4 shows photograph of pityriasis versicolor as seen through woods lamp magnifier showing green-yellow fluorescence. Early diagnosis facilitated by this technique allows for the timely initiation of appropriate therapy, thereby improving patient outcomes and reducing the risk of complications.

Ethical approval

Institutional Review Board approval is not required.

Declaration of patient consent

The authors certify that they have obtained all appropriate patient consent.

Financial support and sponsorship

Nil.

Conflicts of interest

There are no conflicts of interest.

Use of artificial intelligence (AI)-assisted technology for manuscript preparation

The authors confirm that there was no use of artificial intelligence (AI)-assisted technology for assisting in the writing or editing of the manuscript and no images were manipulated using AI.

How to cite this article: Patil S, Bhatnagar A, Mitra D. Bedside Demonstration of Fluorescence Using 365 nm Wood's Lamp Mode of Dermoscope in Pityriasis Versicolor. *Indian J Postgrad Dermatol.* 2024;2: 150-1. doi: 10.25259/IJPGD_46_2024