

Image Correspondence

Reticulate Pigmentation Over the Back

Suchismita Dalai¹, Jayashree Mohanty¹, Siddhartha Dash¹

¹Department of Dermatology and Venereology, S.C.B. Medical College and Hospital, Cuttack, Odisha, India.

*Corresponding author:

Siddhartha Dash,
Department of Dermatology,
and Venereology, S.C.B.
Medical College and Hospital,
Cuttack, Odisha, India.

siddharth101990@gmail.com

Received: 16 July 2024
Accepted: 06 December 2024
Epub Ahead of Print: 21 January 2025
Published: 07 February 2025

DOI
10.25259/IJPGD_154_2024

Quick Response Code:



A 34-year-old male presented with asymptomatic brownish flat lesions over back for 6 months. On cutaneous examination, the lesion was greyish-brown, scaly plaque which was confluent at the centre and had a peripheral reticulated pattern [Figure 1a]. General and systemic examination was unremarkable. Dermoscopy (Dermlite DL4, ×10 magnification) revealed flat, light-brown globules in a cobblestone pattern along with fine, white scales [Figure 1b]. Histopathology showed hyperkeratosis, low broad papillomatosis, mild acanthosis, mild increase in melanin pigment and perivascular lymphocytic infiltration in dermis [Figure 1c]. Based on clinico-dermoscopic and histopathological findings, final diagnosis of confluent and reticulated papillomatosis was made. There was complete resolution of lesions after treatment with oral minocycline 100 mg once daily in the next 30 days [Figure 1d]. Clinical and dermoscopic differentials have been discussed in Table 1.^[1]

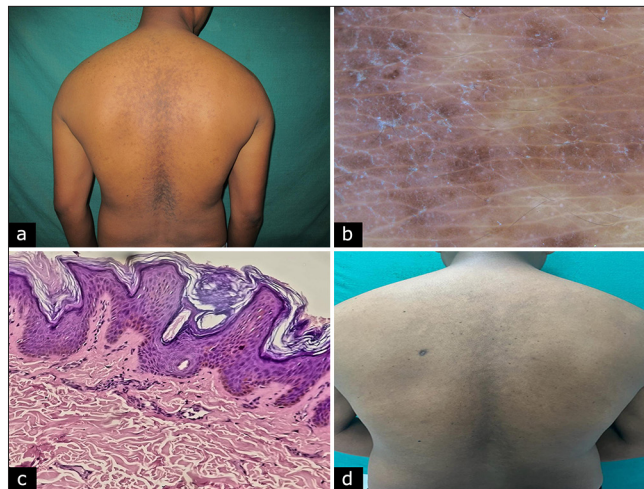


Figure 1: (a) Greyish-brown, scaly plaque over the back, confluent at the centre and reticulated at the periphery. (b) Dermoscopy with Dermlite DL4 under ×10 magnification revealed fine, whitish scaling and flat, light-brown globules in a cobblestone pattern. (c) hyperkeratosis, low broad papillomatosis, mild acanthosis, mild increase in melanin pigment and perivascular lymphocytic infiltration in dermis (haematoxylin and eosin, ×100). (d) Near complete improvement after treatment.

This is an open-access article distributed under the terms of the Creative Commons Attribution-Non Commercial-Share Alike 4.0 License, which allows others to remix, transform, and build upon the work non-commercially, as long as the author is credited and the new creations are licensed under the identical terms.

©2025 Published by Scientific Scholar on behalf of Indian Journal of Postgraduate Dermatology

Table 1: Clinical and dermoscopic differentials of CARP.

Skin disorder	Clinical findings	Dermoscopic findings
CARP	Asymptomatic, greyish-brown, scaly, flat papules that coalesce into larger patches with a reticulated pattern at the periphery	Brownish areas in a cobblestone or 'sulci and gyri' pattern with white scales
Pityriasis versicolor	Asymptomatic, perifollicular, greyish-brown, scaly macules and patches	Faint pigment network composed of brownish stripes and fine scales
Terra firma-forme dermatosis	Asymptomatic, thickened brown-black papules and plaques	Large, polygonal plate-like brown scales arranged in a mosaic pattern
Erythema ab igne (pigmented stage)	Brownish patches arranged in lace-like or fishing net pattern	Homogenous brownish pigmentation with or without linear branching vessels or white scales
Dowling-Degos disease	Asymptomatic, reticulate brownish macules over the flexures	Brownish star-like area or irregular brownish projections with a hypopigmented centre over a brownish/reddish brown background

CARP: Confluent and reticulated papillomatosis

Ethical approval: Institutional Review Board approval is not required.

Declaration of patient consent: The authors certify that they have obtained all appropriate patient consent.

Financial support and sponsorship: Nil.

Conflicts of interest: There are no conflicts of interest.

Use of artificial intelligence (AI)-assisted technology for manuscript preparation: The authors confirm that there was no use of artificial intelligence (AI)-assisted technology for assisting in the writing or editing of the manuscript and no images were manipulated using AI.

REFERENCE

1. Errichetti E, Maione V, Stinco G. Dermatoscopy of Confluent and Reticulated Papillomatosis (Gougerot-Carteaud Syndrome). *J Dtsch Dermatol Ges* 2017;15:836-8.

How to cite this article: Dalai S, Mohanty J, Dash S. Reticulate Pigmentation Over the Back. *Indian J Postgrad Dermatol*. 2025;3:79-80. doi: 10.25259/IJPGD_154_2024