

## Case Report

# Dew Drops Over Skin: A Rare Case of Miliaria Crystallina in an Adult Female with Pemphigus Vulgaris

Prachi Sanjay Gaikwad<sup>1</sup>, Nachiket Madhukarrao Palaskar<sup>1</sup>, Yuvraj Eknath More<sup>1</sup>, Shubham Suraj Gadkar<sup>1</sup>

<sup>1</sup>Department of Dermatology, Venereology and Leprosy, PCMC's PGI YCM Hospital, Pune, Maharashtra, India.

### \*Corresponding author:

Prachi Sanjay Gaikwad,  
Department of Dermatology,  
Venereology and Leprosy,  
PCMC's PGI YCM Hospital,  
Pune, Maharashtra, India.  
[psgaikwad57@gmail.com](mailto:psgaikwad57@gmail.com)

Received: 28 July 2024

Accepted: 09 December 2024

Published: 07 February 2025

### DOI

10.25259/IJPGD\_168\_2024

### Quick Response Code:



## ABSTRACT

Miliaria crystallina occurs due to sweat duct obstruction and sweat retention into the stratum corneum. Miliaria is common in infants due to immaturity of eccrine glands. Heat, humidity, fever and a few drugs (e.g., isotretinoin and bethanechol) are known predisposing factors for the development of miliaria. To the best of our knowledge, miliaria has not been reported in patients with pemphigus vulgaris.

**Keywords:** Eccrine glands, Heat rash, Miliaria crystallina, Sweat retention

## INTRODUCTION

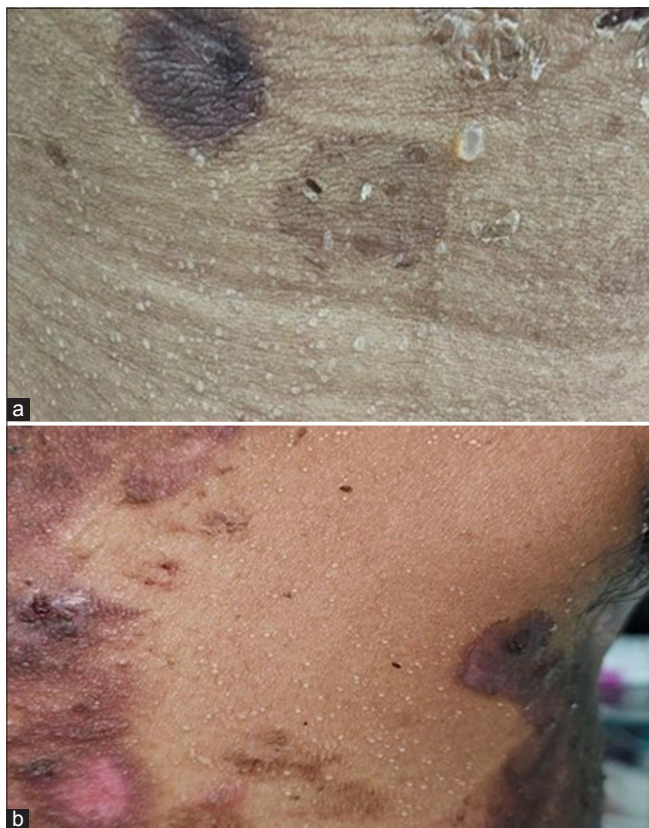
Miliaria crystallina, also known as sweat rash or prickly heat, is an asymptomatic condition characterised by sweat retention due to blockage in the eccrine sweat ducts.<sup>[1]</sup> It is more frequent in infants, neonates and young children, whereas it is less common in adults.<sup>[2]</sup> Predisposing factors include over-wrapping of clothes, fever, occlusive dressings, lack of air conditioning in warm climates and few drugs.<sup>[2]</sup> Here, we discuss a rare case of miliaria crystallina in an adult female with pemphigus vulgaris, highlighting its occurrence in an atypical population.

## CASE REPORT

A 26-year-old female, biopsy-proven case of pemphigus vulgaris, was admitted to the dermatology ward for dexamethasone cyclophosphamide pulse (DCP), 1<sup>st</sup> cycle of Phase 1. On 3<sup>rd</sup> day of DCP, she suddenly developed multiple, tiny, clear fluid-filled vesicles over her trunk. These vesicles were not associated with redness, itching or fever. On examination, there were multiple tiny vesicles of size ranging from 3 to 8 mm in diameter, without surrounding erythema. The lesions were filled with clear fluid and were looking like dew drops discretely distributed over the chest, axillae and lower abdomen [Figure 1]. Tzanck smear from these vesicles was unremarkable. Based on history, clinical examination and Tzanck smear, we concluded that the patient was suffering from miliaria crystallina, also known as heat rash or sudamina. The patient was shifted to a relatively cooler, well-ventilated room. The lesions improved and eventually cleared up on their own by desquamation within 48 h without leaving behind any pigmentation or scarring [Figure 2].

This is an open-access article distributed under the terms of the Creative Commons Attribution-Non Commercial-Share Alike 4.0 License, which allows others to remix, transform, and build upon the work non-commercially, as long as the author is credited and the new creations are licensed under the identical terms.

©2025 Published by Scientific Scholar on behalf of Indian Journal of Postgraduate Dermatology



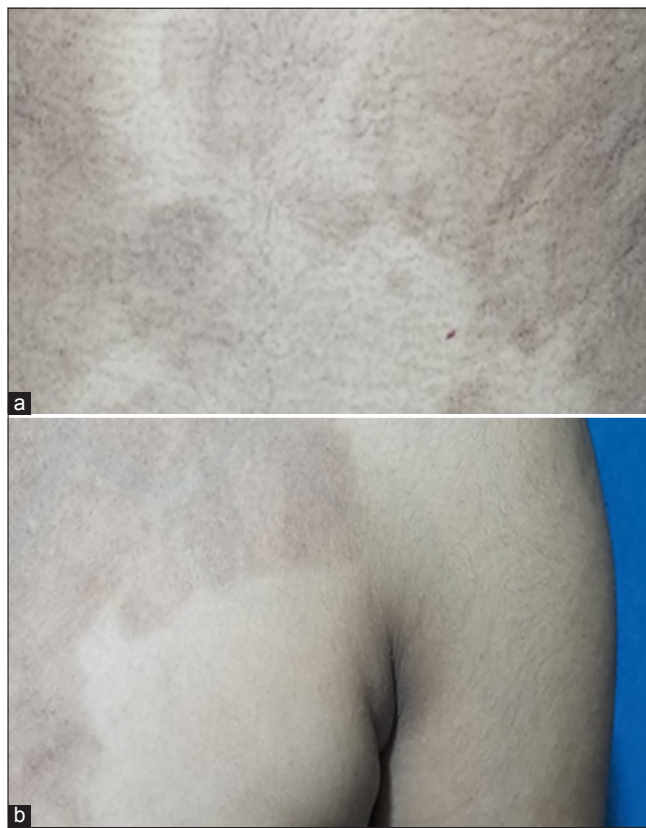
**Figure 1:** (a, b) Multiple well-defined pinhead-sized clear fluid vesicles without surrounding erythema present over abdomen and left axilla. Note: Post-inflammatory hyperpigmented macules due to healed lesions of pemphigus vulgaris.

## DISCUSSION

In humans, there are three main types of sweat glands: eccrine, apocrine and apoeccrine. Amongst these, eccrine glands are the most abundant and present throughout the body.<sup>[2]</sup> They are mainly stimulated by sympathetic nerves, using cholinergic fibres.<sup>[3]</sup> Eccrine sweat glands respond primarily to core body temperature and skin temperature, as well as adrenergic activation and exercise-related non-thermal factors.<sup>[3]</sup>

In miliaria, keratinous plugs block eccrine sweat ducts, trapping sweat and resulting in retrograde pressure. It causes duct rupture, which allows the sweat to seep into dermis and epidermis. Miliaria is of three types based on the depth of the anatomical blockage of the eccrine sweat glands: crystallina, rubra and profunda.<sup>[4]</sup>

Miliaria crystallina, the most common type, occurs due to blockage at the stratum corneum. Miliaria rubra and profunda occur due to blockage at the subcorneal layers and the dermal-epidermal junction, specifically the papillary dermis respectively.



**Figure 2:** (a, b) Post-inflammatory hyperpigmented macules due to resolved lesions of pemphigus vulgaris, over abdomen and left axilla with a resolution of miliaria after 2 weeks of follow-up.

Miliaria is commonly reported in newborns and critically ill patients with fever in the intensive care unit. Few medications and warm and humid environment are also predisposing factors for miliaria.

In our case, an adult female with pemphigus vulgaris experienced miliaria crystallina, causing her anxiety and worry. She mistakenly believed that the new acute rash was related to her pemphigus vulgaris despite being on treatment.

Viral infections (herpes simplex or varicella), arthropod bites, new lesions of pemphigus vulgaris, acute generalised exanthematous pustulosis, Grover disease and allergic dermatitis should be considered as differential diagnoses of miliaria.<sup>[4,5]</sup> The absence of erythema around lesions, itching and burning sensation, fever and considering the patient's age, effectively ruled out these differentials.

## CONCLUSION

The association of miliaria crystallina in pemphigus vulgaris has not been previously reported. Our patient did not develop miliaria on subsequent pulses of DCP. Warm and humid climatic conditions were the probable precipitating factors for miliaria in our case.

**Ethical approval:** Institutional Review Board approval is not required.

**Declaration of patient consent:** The authors certify that they have obtained all appropriate patient consent.

**Financial support and sponsorship:** Nil.

**Conflicts of interest:** There are no conflicts of interest.

**Use of artificial intelligence (AI)-assisted technology for manuscript preparation:** The authors confirm that there was no use of artificial intelligence (AI)-assisted technology for assisting in the writing or editing of the manuscript and no images were manipulated using AI.

2. Papadatos SS, Toliaki E, Kardatou ME, Galani V, Kalfountzos D. Water Drops All Over the Skin: Miliaria Crystallina in an Adult Febrile Patient with Glioblastoma. *Maedica* 2023;18:534.
3. Shibasaki M, Crandall CG. Mechanisms and Controllers of Eccrine Sweating in Humans. *Front Biosci (Schol Ed)* 2010;2:685.
4. Guerra KC, Toncar A, Krishnamurthy K. Miliaria. In: StatPearls. Treasure Island, FL: StatPearls; 2023.
5. Eshaqi FJ, Almaa ZA, Samiey F, Al Awadhi A. An Unusual Presentation of Heat Rash: Bullous Miliaria in a Middle-aged Woman. *Cureus* 2022;14:e25323.

## REFERENCES

1. El Anzi O, Hassam B. Widespread Miliaria Crystallina: About a Case. *Pan Afr Med J* 2018;30:69.

**How to cite this article:** Gaikwad PS, Palaskar NM, More YE, Gadkar SS. Dew Drops Over Skin: A Rare Case of Miliaria Crystallina in an Adult Female with Pemphigus Vulgaris. *Indian J Postgrad Dermatol.* 2025;3:49-51. doi: 10.25259/IJPGD\_168\_2024