

Image Correspondence

Videodermoscopy of Cutaneous Wound Myiasis

Pooja Kotian¹, Keshavmurthy A. Adya¹, Arun C. Inamadar¹

¹Department of Dermatology, Venereology and Leprosy, Shri B M Patil Medical College Hospital and Research Centre, BLDE (Deemed to be University), Vijayapur, Karnataka, India.

***Corresponding author:**

Arun C. Inamadar,
Department of Dermatology,
Venereology and Leprosy,
Shri B M Patil Medical
College Hospital and Research
Centre, BLDE (Deemed to
be University), Vijayapur,
Karnataka, India.

aruninamadar@gmail.com

Received: 17 February 2023
Accepted: 11 May 2023
Epub Ahead of Print: 07 June 2023
Published: 28 September 2023

DOI
10.25259/IJPGD_21_2023

Quick Response Code:



An elderly male with long-standing Type 2 diabetes presented with a chronic wound over the right foot. On examination, a solitary punched-out plantar ulcer with hyperkeratotic margins measuring about 3 × 2 cm was noted [Figure 1a]. Floor of the ulcer showed yellowish slough containing grey

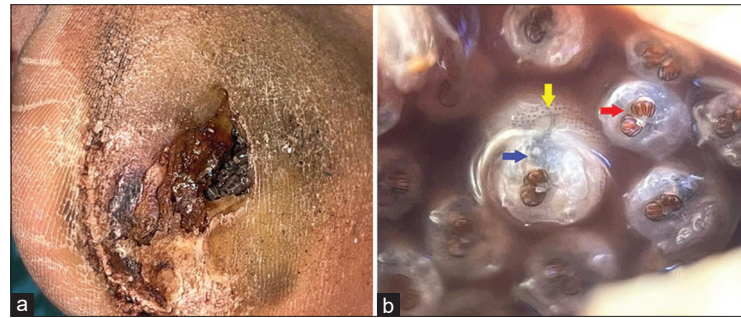


Figure 1: Punched-out ulcer with hyperkeratotic margins showing yellowish slough and multiple greyish larvae (a). Dermoscopy shows multiple mobile and greyish-white larvae with respiratory spiracles (b, red arrow), pigmented tracheal tubes (b, blue arrow) and circumferential brown dots (b, yellow arrow). (Polarised dermoscopy [DermLite™ DL3, 3Gen Inc., San Juan Capistrano, CA, USA], ×10).



Video 1: Video dermoscopy showing live mobile larvae and their morphological characteristics. (Polarised dermoscopy [DermLite™ DL3, 3Gen Inc., San Juan Capistrano, CA, USA], ×10).

This is an open-access article distributed under the terms of the Creative Commons Attribution-Non Commercial-Share Alike 4.0 License, which allows others to remix, transform, and build upon the work non-commercially, as long as the author is credited and the new creations are licensed under the identical terms.

©2023 Published by Scientific Scholar on behalf of Indian Journal of Postgraduate Dermatology

coloured larvae. Polarised dermoscopy revealed multiple, mobile, greyish-white larvae exhibiting respiratory spiracles, pigmented tracheal tubes and circumferential brown dots [Figure 1b and Video 1]. The clinical and dermoscopic features established the diagnosis of wound myiasis. The larvae most probably belonged to the Calliphoridae family based on the morphological characters.^[1]

Wound myiasis refers to infestation of unattended wounds by the larvae of arthropod order Diptera. Dermoscopy assists not only in confirming the diagnosis by *in vivo* visualisation of larvae; it also helps in species identification and assists removal of the larvae not visible to the naked eye.

Declaration of patient consent

Patient's consent not required as patient's identity is not disclosed or compromised.

Financial support and sponsorship

Nil.



Conflicts of interest

There are no conflicts of interest.

REFERENCE

- Gontijo JR, Bittencourt FV. Wound myiasis: The role of entodermoscopy. *An Bras Dermatol* 2018;93:746-8.


How to cite this article: Kotian P, Adya KA, Inamadar AC. Videodermoscopy of Cutaneous Wound Myiasis. *Indian J Postgrad Dermatol* 2023;1:138-9.






ScientificScholar


Knowledge is power

SIGN IN










Login

Forgot your password?
Don't have an account? [Register Now](#)

Indian Journal of Postgraduate Dermatology



<https://ijpgderma.org>

© EditorialAssist - A product of Scientific Scholar LLC
 Build Version: 1.7.65