



Case Report

Hidradenoma Papilliferum Mimicking Pyogenic Granuloma

Komal Nana Nikam¹, Yuvraj Eknath More¹, Nachiket Madhukarrao Palaskar¹

¹Department of Dermatology, Venerology and Leprosy, Pimpri Chinchwad Municipal Corporation (PCMC's) Post Graduate Institute, Yashwantrao Chavan Memorial (YCM) Hospital, Pune, Maharashtra, India.

*Corresponding author:

Komal Nana Nikam,
Department of Dermatology,
Venerology and Leprosy,
Pimpri Chinchwad Municipal
Corporation (PCMC's) Post
Graduate Institute, Yashwantrao
Chavan Memorial (YCM)
Hospital, Pune, Maharashtra,
India.

shamicanikam@gmail.com

Received: 26 November 2023
Accepted: 20 February 2024
Epub Ahead of Print: 12 April 2024
Published: 23 August 2024

DOI

10.25259/IJPGD_115_2023

Quick Response Code:



ABSTRACT

Hidradenoma papilliferum is a rare, benign apocrine tumour that occurs almost exclusively in the anogenital region of middle aged women. Here, we present a case of a 28-year-old married female presenting with asymptomatic, erythematous nodule over left labia majora mimicking pyogenic granuloma. A surgical excision was done and histopathological examination revealed the diagnosis of hidradenoma papilliferum.

Keywords: Hidradenoma papilliferum, Vulval nodule, Pyogenic granuloma

INTRODUCTION

Hidradenoma papilliferum is a rare, benign apocrine tumour that occurs most commonly in the genital region of middle-aged women. It usually occurs as an asymptomatic, solid, well-defined, skin or red-coloured nodule,^[1-4] mostly in the vulvar and perianal areas and less frequently in extragenital areas such as the nose, eyelid, arms and chest.

CASE REPORT

A 28-year-old married female presented to our department with the complaint of a single soft red-coloured mass over the outer aspect of the left side of her external genitalia for 2 months. It was insidious in onset and gradually progressive to the present size of a pea [Figure 1].

She gave history of a single episode of slight bleeding on trivial touch 15 days back. It was not associated with pain, itching or ulceration. The patient denied any history of high-risk behaviour. Cutaneous examination revealed a single well-defined erythematous exuberant nodule of size 1.5 × 1 × 1 cm with an irregular surface present over the outer aspect and lower 1/3rd of left labia majora. It was mobile, cystic and non-tender on palpation. The general physical and systemic examination including lymph nodes were unremarkable. Based on the history and clinical examination, differential diagnoses of pyogenic granuloma, hidradenoma papilliferum and donovanosis were made. Complete blood count was within normal limits. Human immunodeficiency virus, hepatitis B surface antigen, hepatitis C virus and venereal disease research laboratory tests were negative.

Giemsa stain of the crushed smear was negative for Donovan bodies. Surgical excision was performed and the specimen was sent for histopathological examination. Biopsy revealed a well-

This is an open-access article distributed under the terms of the Creative Commons Attribution-Non Commercial-Share Alike 4.0 License, which allows others to remix, transform, and build upon the work non-commercially, as long as the author is credited and the new creations are licensed under the identical terms.

©2024 Published by Scientific Scholar on behalf of Indian Journal of Postgraduate Dermatology

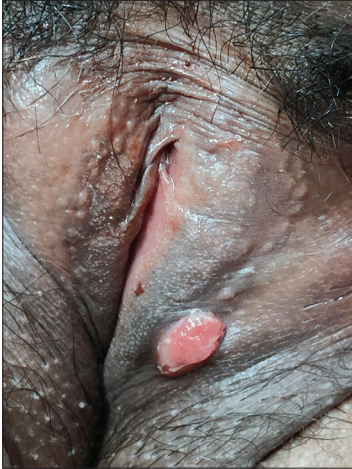

Figure 1: A 1.5*1 cm sized single soft red-coloured nodule over the outer aspect of the left side of external genitalia.

circumscribed tumour located underlying the epidermis. It was composed of slender fronds of connective tissue lined by an outer columnar epithelial layer which showed an oval, pale-staining nucleus near the base with faintly eosinophilic cytoplasm and inner myoepithelial cells layer with deeply basophilic nuclei. Mitotic figures were absent [Figure 2]. It was histologically suggestive of hidradenoma papilliferum.

DISCUSSION

Hidradenoma papilliferum was first described by Worth in the year 1878; it originates from the apocrine glands. It is a benign nodular lesion frequently seen in middle-aged women.^[5] The most common site is the labia majora. It can also be present over the clitoris, posterior fourchette, perineum and anal region.^[1-5] Most cases show a single asymptomatic nodule. However, mild tenderness can also be present.^[6,7] Rare forms called ectopic hidradenoma papilliferum are described in areas containing modified apocrine glands, such as the eyelid, outer ear and male and female breast.^[8] Most authors say that lesions like these originate from breast-like apocrine glands.^[9] Its differential diagnosis include mucous cysts, lipoma, haemorrhoids, anorectal abscess, viral verrucous lesions, syringocystadenoma papilliferum and sebaceous cysts and a few malignant lesions such as squamous cell carcinoma and metastatic papillary carcinoma to be ruled out before its diagnosis.^[10]

Histopathological examination reveals a well-circumscribed tumour surrounded by a fibrous capsule. There are tubular and cystic structures present within the tumour. Cystic spaces have projections of papillary folds. Usually, the lumina are surrounded by a double layer of cells. These consist of an inner layer of secretory columnar cells and an outer layer of small cuboidal myoepithelial cells with deeply basophilic nuclei.

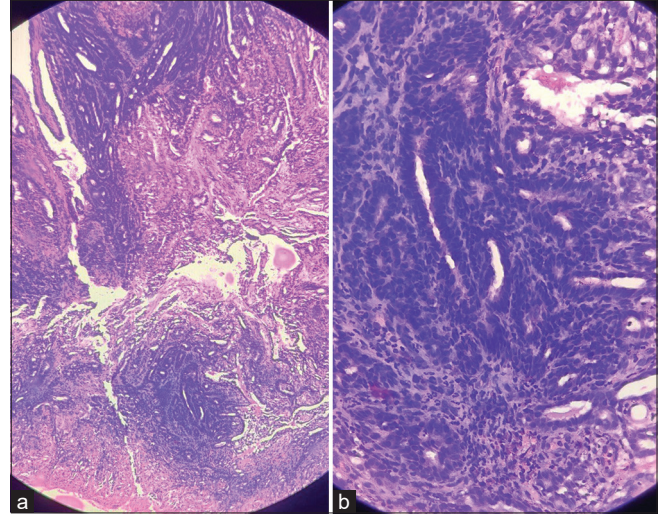


Figure 2: Haematoxylin-Eosin-stained section - (a) $\times 10$ magnification view showing slender fronds of connective tissue. (b) $\times 40$ magnification view showing an outer columnar epithelial layer and inner myoepithelial cells layer.

Rarely, only a single row of columnar cells, which show an oval, pale-staining nucleus located near the base with faintly eosinophilic cytoplasm and active decapitation secretion like secretion of apocrine glands can be present surrounding the lumina. In some studies, human papillomavirus types 16, 31, 33, 53 and 56 DNA are found in hidradenoma papilliferum. However, no role of human papilloma virus has been proven in the etiopathogenesis of hidradenoma papilliferum.^[11]

CONCLUSION

When a sexually active woman presents with a nodular lesion over the vulva, though rare, “hidradenoma papilliferum” should be kept in mind. It may mimic other vulval lesions such as pyogenic granuloma or Bartholin cyst. Therefore, surgical excision and histopathological examination are of paramount importance.

Ethical approval

Institutional Review Board approval is not required.

Declaration of patient consent

The authors certify that they have obtained all appropriate patient consent.

Financial support and sponsorship

Nil.

Conflicts of interest

There are no conflicts of interest.

Use of artificial intelligence (AI)-assisted technology for manuscript preparation

The authors confirm that there was no use of artificial intelligence (AI)-assisted technology for assisting in the writing or editing of the manuscript and no images were manipulated using AI.

REFERENCES

1. Tanaka M, Shimizu S. Hidradenoma Papilliferum Occurring On the Chest of a Man. *J Am Acad Dermatol* 2003;48:S20-1.
2. Virgili A, Marzola A, Corazza M. Vulvar Hidradenoma Papilliferum. A Review of 10.5- Years' Experience. *J Reprod Med* 2000;45:616-8.
3. Handa Y, Yamanaka N, Inagaki H, Tomita Y. Large Ulcerated Perianal Hidradenoma Papilliferum in a Young Female. *Dermatol Surg* 2003;29:790-2.
4. Kim YJ, Lee JW, Choi SJ, Kim SJ, Kim YJ, Jeon YS, *et al.* Ectopic Hidradenoma Papilliferum of the Breast: Ultrasound Finding. *J Breast Cancer* 2011;14:153-5.
5. Woodworth H Jr, Dockerty MB, Wilson RB, Pratt JH. Papillary Hidradenoma of the Vulva: A Clinicopathologic Study of 69 Cases. *Am J Obstet Gynecol* 1971;110:501-8.
6. Alegría-Landa V, Jo-Velasco M, Requena L. Perianal Nodule in a Young Woman. *Clin Exp Dermatol* 2019;44:96-8.
7. Spindler L, Pommaret E, Barracco MM, Fathallah N, Plantier F, Duchatelle V, *et al.* Anal and Vulvar Hidradenoma Papilliferum are Similar: A Study of 14 Cases. *Ann Dermatol Venereol* 2019;146:537-41.
8. Vang R, Cohen PR. Ectopic Hidradenoma Papilliferum: A Case Report and Review of the Literature. *J Am Acad Dermatol* 1999;41:115-8.
9. Theodosiou G, Zafeiriadou V, Papageorgiou M, Mandekou-Lefaki I. An Unusual Lesion in the Right Place. *Dermatol Pract Concept* 2016;6:7-9.
10. Hernández-Angeles C, Nadal A, Castelo-Branco C. Hidradenoma Papilliferum of the Vulva in a Postpartum Woman: A Case Report. *J Obstet Gynaecol* 2017;37:683-4.
11. Kazakov DV, Spagnolo DV, Kacerovska D. Lesions of Anogenital Mammary-Like Glands: An Update. *Adv Anat Pathol* 2011;18:1-28.

How to cite this article: Nikam KN, More YE, Palaskar NM. Hidradenoma Papilliferum Mimicking Pyogenic Granuloma. *Indian J Postgrad Dermatol.* 2024;2:89-91. doi: 10.25259/IJPGD_115_2023