

## Case Report

# Pustular Psoriasis of Pregnancy Successfully Managed with Steroid and Cyclosporine – A Case Report

Niraj Virendrabhai Dhinoja<sup>1</sup>, Mauli Shah<sup>1</sup>, Kishan Jadav<sup>1</sup>, Rita Vora<sup>1</sup>

<sup>1</sup>Department of Dermatology, Venereology and Leprosy, Pramukhswami Medical College and Shree Krishna Hospital, Bhaikaka University, Karamsad, Gujarat, India.

### \*Corresponding author:

Rita Vora,  
Department of Dermatology,  
Venereology and Leprosy,  
Pramukhswami Medical  
College and Shree Krishna  
Hospital, Bhaikaka University,  
Karamsad, Gujarat, India.

[ritavv@charutarhealth.org](mailto:ritavv@charutarhealth.org)

Received: 25 October 2023  
Accepted: 03 March 2024  
Epub Ahead of Print: 03 June 2024  
Published: 23 August 2024

### DOI

10.25259/IJPGD\_104\_2023

### Quick Response Code:



## ABSTRACT

Pustular psoriasis of pregnancy is a well-known dermatosis of pregnancy. Erythematous plaques with pustular rings and central erosions affecting the intertriginous regions are one of the most common presentations. It can be severe during pregnancy and may impact both the mother and the foetus if not treated. It typically disappears quickly after birth, but there is a chance of recurrence with increased severity in consecutive pregnancies. Systemic corticosteroids are the treatment of choice in generalised pustular psoriasis of pregnancy (GPPP). Cyclosporine also plays a role in the management. We present a case of GPPP in a 30-year-old woman who was treated with systemic corticosteroids and cyclosporine with an uneventful childbirth and a normal foetus.

**Keywords:** Pustular psoriasis of pregnancy, Systemic corticosteroids, Cyclosporine, Intrauterine growth retardation, Neutrophilic inflammatory infiltrate

## INTRODUCTION

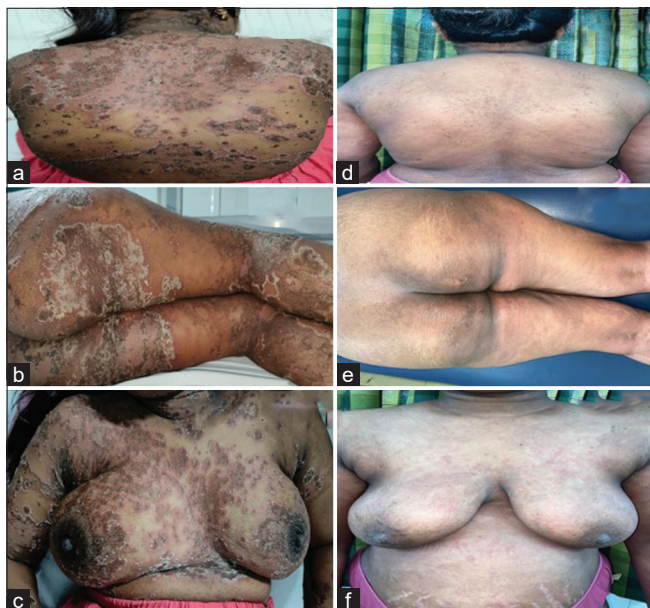Pustular psoriasis of pregnancy (PPP) is a severe type of psoriasis characterised by the development of skin pustules.<sup>[1]</sup> Typically, this condition presents in the first trimester and may last through the postpartum period, with resolution occurring after delivery.<sup>[2]</sup> Due to the potential repercussions on both the mother and foetus, generalised PPP (GPPP) becomes a notable concern during pregnancy. We present a case of GPPP in a 30-year-old female treated with systemic corticosteroids and cyclosporine.

## CASE REPORT

A 30-year-old pregnant woman, weighing 60 kg, presented with multiple pus-filled lesions on her face, chest, abdomen, back, upper and lower limbs since 1 month, accompanied by pain and burning sensation. She had a history of intermittent fever, with lesions exacerbating during the temperature spikes. Similar, but milder symptoms were noted during her previous pregnancy. No other systemic complaints or autoimmune conditions were reported. No similar history was seen in the family. A cutaneous examination revealed erythematous to hyperpigmented tender plaques ranging from size 3×3 cm<sup>2</sup> to 5×6 cm<sup>2</sup>, over the back [Figure 1a], buttocks [Figure 1b], chest including breasts [Figure 1c], face, axillae, abdomen, and groin, accompanied by pinpoint pustular lesions at the periphery. There was symptomatic improvement on treatment [Figure 1d-f]. Obstetric examination revealed 28 weeks of pregnancy with a healthy foetus confirmed by baseline ultrasonography at 29 weeks of gestation.

This is an open-access article distributed under the terms of the Creative Commons Attribution-Non Commercial-Share Alike 4.0 License, which allows others to remix, transform, and build upon the work non-commercially, as long as the author is credited and the new creations are licensed under the identical terms.

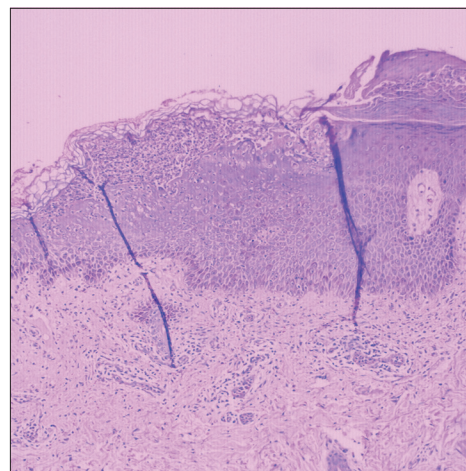
©2024 Published by Scientific Scholar on behalf of Indian Journal of Postgraduate Dermatology



**Figure 1:** Multiple erythematous to hyperpigmented tender annular plaque of size approximately 3×3 to 5×6 cm studded with pinhead size pustular lesions on peripheral rim over (a) back, (b) bilateral buttocks and lower limbs, (c) chest and lesions healed post treatment over (d) back, (e) bilateral buttocks and lower limbs, (f) chest.

Laboratory tests showed elevated total counts, low haemoglobin, low Vitamin D3, decreased total calcium, raised serum alkaline phosphatase, raised C-reactive protein, erythrocyte sedimentation rate (ESR) and low albumin. Culture and sensitivity report of pus showed growth of normal skin flora. A skin punch biopsy from a pustular lesion over the right arm revealed hyperplastic squamous epithelium with focal parakeratosis and Munro's microabscess containing neutrophils and necrotic debris. Intraepidermal spongiform pustules of Kogoj were also present. The dermis showed perivascular lymphoplasmacytic and polymorphonuclear infiltrate [Figure 2].

The patient was diagnosed with GPPP and treated with systemic steroids, antibiotics, antihistamines and supportive medications. Oral prednisolone in a dose of 30 mg daily was given for 7 days on an outpatient basis. However, the patient complained of appearance of new lesions and systemic symptoms, after which she was admitted and Inj. Dexamethasone was started at a dose of 8 mg daily for 5 days along with intravenous antibiotics and antihistamine. Due to the appearance of new lesions, cyclosporine was added at 3 mg/kg dose (100 mg twice daily) and the patient was shifted to Tab. Prednisolone 60 mg daily. The patient was discharged after 10 days on Tab. Prednisolone 60 mg once daily along with Tab. Cyclosporine 100 mg twice daily for 1 week. Tab. Prednisolone was tapered to 50 mg once daily and 40 mg once daily over the next 2 weeks. Tab. Cyclosporine was continued on the same dose and then reduced to 50 mg twice daily until the due date.



**Figure 2:** Histopathology (Haematoxylin and eosin staining, ×10), hyperkeratosis and parakeratosis, Munro's microabscesses, Spongiform pustules of Kogoj, Flattening of rete ridges and Perivascular mixed inflammatory infiltrate.

At 34 weeks, a caesarean section was performed due to reversal of flow on foetal Doppler indicating intrauterine growth retardation. No foetal anomalies were found, indicating the safe use of steroids and cyclosporine in pregnancy.

## DISCUSSION

PPP is an uncommon illness that affects pregnant women in their third trimester or after giving birth.<sup>[2]</sup> Von Hebra *et al.* were the first to describe it, with systemic symptoms and pustular skin eruption.<sup>[3]</sup> It is an immune dysregulation illness commonly associated with other psoriasis subtypes. Interleukin (IL)-1 and IL-36 are essential in persistent neutrophil chemotaxis and pustule development and overlap with plaque psoriasis.<sup>[4]</sup> Genetic mutations, including IL36RN, can predispose people to GPP, which usually settles after parturition but is very likely to reoccur in consecutive pregnancies. PPP flares have also been connected to oral contraceptive use and menstrual cycle alterations.<sup>[5]</sup>

PPP appears as erythematous plaques with a pustular ring and central erosion in intertriginous regions, sometimes affecting the entire skin surface. The cheeks, palms and soles are usually untouched. Patients may have symptoms such as fatigue, fever, diarrhoea, dehydration, tachycardia and convulsions. Laboratory findings commonly show leucocytosis, increased ESR and negative cultures from pustules and peripheral blood. Diagnosis is primarily based on clinical and histopathological evidence, demonstrating neutrophilic inflammatory infiltrates, acanthosis and papillomatosis with focal parakeratosis, including characteristic spongiform pustules of Kogoj.<sup>[6]</sup> Pustular psoriasis, dermatitis herpetiformis, acute generalised exanthematous pustulosis, polymorphic eruption of

pregnancy, atopic eruption of pregnancy, subcorneal pustular dermatosis and gestational pemphigoid are all differential diagnoses.<sup>[2]</sup> During pregnancy, systemic corticosteroids with 30–60 mg of prednisone per day are the preferred therapy. Pregnant women suffering from moderate PPP may be treated with low-dose prednisolone (15–30 mg/day), while severe cases may require higher doses (60–80 mg/day). Steroids suppress the hypothalamic-pituitary axis and disrupt the normal hormonal balance in the body, potentially affecting the placenta's function and nutrient supply to the developing foetus. This can lead to decreased foetal growth and an increased risk of complications. Foetal lung maturity is important as foetus is prone to preterm birth in GPPP and intravenous dexamethasone helps in foetal lung maturity, which is why this molecule was preferred instead of up dosing the oral prednisolone. In pregnancy, combining steroids with Cyclosporine, a category C medication, is beneficial in moderate to severe cases.<sup>[7]</sup> Steroids are used as a first-line treatment to reduce the disease activity promptly and most patients improve with steroids monotherapy. However, in refractory cases, cyclosporine is beneficial and safe. Combination of steroids and cyclosporine is better because both promptly decrease the disease activity and gives better maternal and foetal outcome. Steroids can be tapered gradually until the due date. While giving steroid caution should be advised during breastfeeding due to uncertain infant exposure effects.<sup>[8]</sup> Some experts recommend taking cephalosporin in conjunction with systemic steroids. Even though systemic steroids and antibiotics have lowered maternal fatalities, stillbirth and perinatal mortality rates remain high due to a variety of problems such as placental insufficiency, premature membrane rupture, preterm labour and intrauterine growth restriction.<sup>[9]</sup> Since the risk of severe recurrences in subsequent pregnancies is considerable, proper patient counselling is critical.

## CONCLUSION

PPP, a controversial aetiology, impairs maternal and foetal health. Early detection, treatment, detailed clinical description and biopsy confirmation are critical for assessing prognosis and pregnancy outcomes. Counselling is crucial throughout pregnancy to minimise mental stress and anxiety. Combining cyclosporine with steroids in the treatment of PPP was useful in our case. Cyclosporine can be given safely weighing the risk-benefit ratio. Collaboration between dermatologists, obstetricians and paediatricians is critical for improving pregnant women's quality of life and ensuring positive foetal health outcomes.

## Acknowledgements

The authors would like to acknowledge the obstetrics and gynaecology medical team and nursing staff.

## Ethical approval

Institutional Review Board approval is not required.

## Declaration of patient consent

The authors certify that they have obtained all appropriate patient consent.

## Financial support and sponsorship

Nil.

## Conflicts of interest

There are no conflicts of interest.

## Use of artificial intelligence (AI)-assisted technology for manuscript preparation

The authors confirm that there was no use of artificial intelligence (AI)-assisted technology for assisting in the writing or editing of the manuscript and no images were manipulated using AI.

## REFERENCES

1. Trivedi MK, Vaughn AR, Murase JE. Pustular Psoriasis of Pregnancy: Current Perspectives. *Int J Womens Health* 2018;10:109-15.
2. Raja A, Palaniappan P, Sankar D, Baalann KP. An Arcane Presentation of Pustular Psoriasis in Pregnancy: Case Report. *Pan Afr Med J* 2022;43:104.
3. Von Hebra F. Regarding Individual Skin Diseases Observed During Pregnancy, The Puerperium and in Uterine Diseases of Women. *Wien Med Wochenschr* 1872;22:1197-202.
4. Johnston A, Xing X, Wolterink L, Barnes DH, Yin Z, Reingold L, *et al.* IL-1 and IL-36 are Dominant Cytokines in Generalized Pustular Psoriasis. *J Allergy Clin Immunol* 2017;140:109-20.
5. Gligora M, Kolavio Z. Hormonal Treatment of Impetigo Herpetiformis. *Br J Dermatol* 1982;107:253.
6. Kondo RN, Araújo FM, Pereira AM, Lopes VC, Martins LM. Pustular Psoriasis of Pregnancy (Impetigo Herpetiformis)-Case Report. *An Bras Dermatol* 2013;88:186-9.
7. Hazarika D. Generalized Pustular Psoriasis of Pregnancy Successfully Treated with Cyclosporine. *Indian J Dermatol Venereol Leprol* 2009;75:638.
8. Flynn A, Burke N, Byrne B, Gleeson N, Wynne B, Barnes L. Two Case Reports of Generalized Pustular Psoriasis of Pregnancy: Different Outcomes. *Obstet Med* 2016;9:55-9.
9. Mohaghegh F, Galehdari H, Rezaie M. Pustular Psoriasis of Pregnancy in Early First Trimester: A Case Report. *Clin Case Rep* 2021;9:e04438.

**How to cite this article:** Dhinoja NV, Shah M, Jadav K, Vora R. Pustular Psoriasis of Pregnancy Successfully Managed with Steroid and Cyclosporine – A Case Report. *Indian J Postgrad Dermatol.* 2024;2:101-3. doi: 10.25259/IJPGD\_104\_2023