



Letter to Editor

Papillon-Lefevre Syndrome: A Tale of Two Cases

J. Dharmender¹, Rutvi Manish Pandya¹, Tejasvi Pravinbhai Patel¹, Kajal Kansara¹, Rima Joshi¹

¹Department of Dermatology, B. J. Medical College and Civil Hospital, Ahmedabad, Gujarat, India.

***Corresponding author:**

Tejasvi Pravinbhai Patel,
Department of Dermatology,
B. J. Medical College and Civil
Hospital, Ahmedabad, Gujarat,
India.

tejasvi.patel2013@gmail.com

Received: 08 January 2024
Accepted: 30 March 2024
Epub Ahead of Print: 23 May 2024
Published: 23 August 2024

DOI
10.25259/IJPGD_5_2024

Quick Response Code:



Dear Editor,

The hereditary palmoplantar keratodermas (PPKs) are a complex group of disorders characterised by thickening of skin of palms and soles in isolation or association with other abnormalities involving nails, teeth or other organs. Their genetic and phenotypic heterogeneity poses a diagnostic challenge, especially in the absence of molecular studies. Here, we present two such cases of PPK with periodontitis. A 25-year-old male born out of a 3rd degree consanguineous marriage presented with skin lesions over bilateral palms and soles since 1 year of age. His deciduous teeth prematurely exfoliated at the age of 4 years. He had a history of extraction of multiple permanent teeth due to mobility. There was history of similar skin lesions in his younger brother. Cutaneous examination revealed diffuse, transgradient keratoderma in a honeycomb pattern over palms and soles that extended onto the dorsal aspect of hands and feet [Figure 1]. Intraoral examination revealed multiple missing teeth with many showing grade 1–3 mobility, caries and plaque accumulation [Figure 2a and b]. Orthopantomogram showed “floating in air” appearance with resorption of alveolar process [Figure 2c].

Second patient was a 21-year-old male born out of non-consanguineous marriage, who presented with thickening of skin over bilateral palms and soles and spontaneous exfoliation of teeth since 3 years of age. On cutaneous examination, diffuse, transgradient PPK over bilateral palms and soles was present, extending onto the dorsal aspect of hands and feet and over tendoachilles [Figure 3a and b]. Psoriasiform plaques were present over bilateral knees and elbows [Figure 3c]. Majority of posterior teeth were lost and many teeth with plaque accumulation and caries were seen on intraoral examination [Figure 3d].

In both patients, there was no evidence of increased sweating, malodour or pseudo-ainhum associated with keratoderma. Oral mucosa and nails were normal. Hearing assessment revealed no abnormality. Lateral skull radiographs in both patients showed no evidence of intracranial calcification. After normal routine blood investigations, both patients were started on oral acitretin 25 mg once daily along with topical moisturiser and keratolytic agent for PPK. The importance of oral hygiene was emphasised and enforcement of oral hygiene habits was advocated. As most of the teeth were involved, extraction of all remaining teeth and fabrication of an immediate removable complete denture (RCD) was planned. Monthly follow-up was advised and satisfactory improvement was noted after 3 months in PPK and periodontitis. Simultaneous orthodontic management and oral rehabilitation was done for their dental problems. However, the second patient was lost to follow-up. To summarise, both of our patients had periodontitis and PPK, while recurrent pyogenic and systemic infection and pseudo-ainhum were absent in both. Looking at the clinical nature of presentation, we kept the diagnosis of Papillon-Lefevre syndrome (PLS). Hence, patients don't need to have all components of a particular syndrome for

This is an open-access article distributed under the terms of the Creative Commons Attribution-Non Commercial-Share Alike 4.0 License, which allows others to remix, transform, and build upon the work non-commercially, as long as the author is credited and the new creations are licensed under the identical terms.

©2024 Published by Scientific Scholar on behalf of Indian Journal of Postgraduate Dermatology

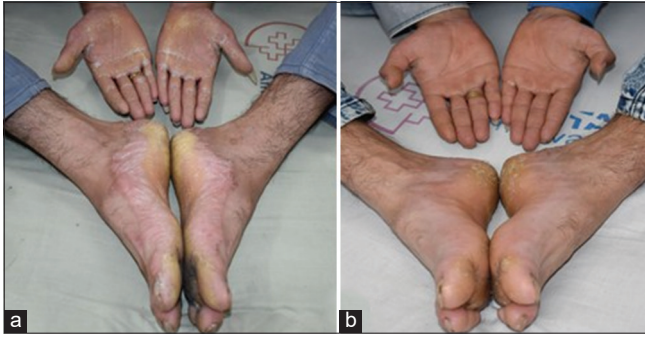


Figure 1: First patient (a) diffuse, transgradient palmoplantar keratoderma over bilateral palms and soles (b) response after 3 months of acitretin.

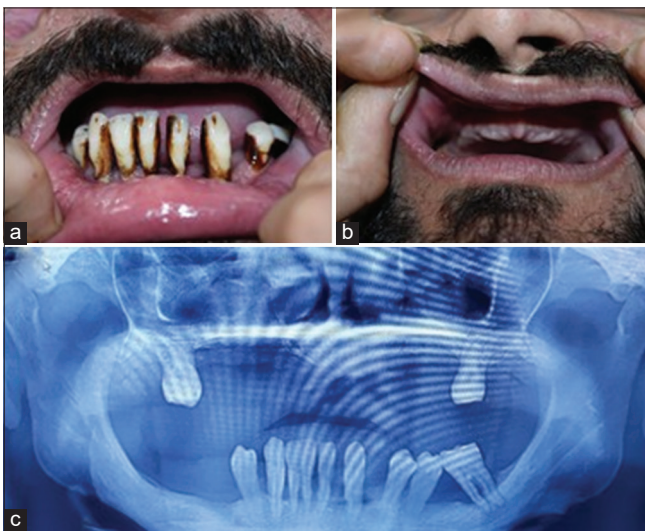

Figure 2: First patient (a) lower teeth showing plaque accumulation and deep periodontal pockets, (b) loss of majority of upper teeth and (c) orthopantomogram showing 'floating in air' appearance with resorption of alveolar process.

diagnosis. Histopathology could not be done due to patient's negative consent. Genetic study of cathepsin C gene (CTSC) for mutations should be done to confirm the diagnosis, though it was not done in our case due to limited resources. Our second patient was born out of a non-consanguineous marriage and had no family history. This may point towards a *de novo* mutation. Further, genetic screening of family members may be required to ascertain the true nature of the mutation. PLS is a rare autosomal recessive disorder of keratinisation characterised by PPK, periodontitis and a tendency for recurrent pyogenic skin and systemic infections. It was originally described in 1924 by two French physicians, Papillon and Lefevre.^[1] It has an estimated prevalence between 1/250,000 and 1/1,000,000 in the general population.^[2] It usually presents during 1st 4 years of life. Although the exact pathogenesis of PLS remains unclear, this condition results from loss-of-function mutations in the

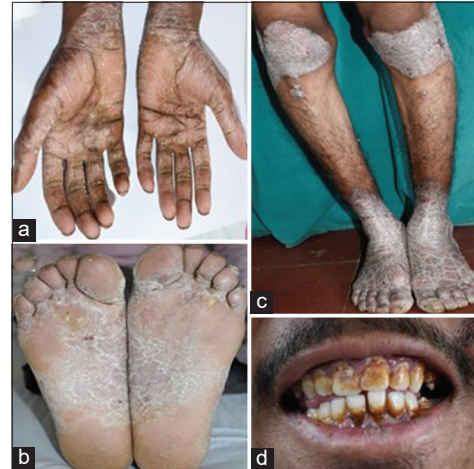

Figure 3: Second patient (a and b) diffuse, transgradient palmoplantar keratoderma over bilateral palms and soles, (c) Psoriasiform plaques over bilateral knees and (d) plaque accumulation and carious teeth.

CTSC gene on chromosome 11q14.1-q14.3.^[3] Haim-Munk syndrome is an allelic variant of PLS. In addition to PPK and periodontitis, they also have arachnodactyly, acroosteolysis and onychogryphosis which were absent in both of our patients.^[4] The skin lesions are usually treated with emollients and keratolytics. Oral retinoids have shown to improve both dermatological and oral lesions.^[5] Systemic antibiotics can be used to reduce the active periodontitis and treat pyogenic infections. Genetic counselling should be offered to the patient, explaining the inheritance pattern of the disease and the probability of offspring being affected.

To conclude, PLS is a rare genodermatosis which can be frustrating to the patient psychologically, socially and aesthetically, and its management is challenging. A holistic approach in liaison with dentist is needed for managing such patients.

Ethical approval

Institutional Review Board approval is not required.

Declaration of patient consent

The authors certify that they have obtained all appropriate patient consent.

Financial support and sponsorship

Nil.

Conflicts of interest

There are no conflicts of interest.

Use of artificial intelligence (AI)-assisted technology for manuscript preparation

The authors confirm that there was no use of artificial intelligence (AI)-assisted technology for assisting in the writing or editing of the manuscript and no images were manipulated using AI.

REFERENCES

1. Fageeh HN. Papillon-Lefèvre Syndrome: A Rare Case Report of Two Brothers and Review of the Literature. *Int J Clin Pediatr Dent* 2018;11:352-5.
2. Dalgic B, Bukulmez A, Sarı S. Eponym: Papillon-Lefevre Syndrome. *Eur J Pediatr* 2011;170:689-91.
3. Hart TC, Bowden DW, Ghaffar KA, Wang W, Cutler CW, Cebeci I, *et al.* Sublocalization of the Papillon-Lefevre Syndrome Locus on 11q14-q 21. *Am J Med Genet* 1998;79:134-9.
4. Rai R, Thiagarajan S, Mohandas S, Natarajan K, Sekar CS, Ramalingam S. Haim Munk Syndrome and Papillon Lefevre Syndrome-Allelic Mutations in Cathepsin C with Variation in Phenotype. *Int J Dermatol* 2010;49:541-3.
5. Sreeramulu B, Shyam ND, Ajay P, Suman P. Papillon-Lefèvre Syndrome: Clinical Presentation and Management Options. *Clin Cosmet Investig Dent* 2015;7:75-81.

How to cite this article: Dharmender J, Pandya RM, Patel TP, Kansara K, Joshi R. Papillon-Lefevre Syndrome: A Tale of Two Cases. *Indian J Postgrad Dermatol.* 2024;2:160-2. doi: 10.25259/IJPGD_5_2024