

Letter to Editor

Monilethrix-like Congenital Hypotrichosis: A Unique Hair Fragility Disorder

Vedashri Vinod Ghatbandhe¹, Uddhao Suresh Zambare¹, Atul Madhusudan Dongre¹, Chitra Nayak¹

¹Department of Skin and Venereal Diseases, Topiwala National Medical College and Bai Yamunabai Laxman Nair Charitable Hospital, Mumbai, Maharashtra, India.

***Corresponding author:**

Uddhao Sure Zambare,
Department of Skin and
Venereal Diseases, Topiwala
National Medical College and
Bai Yamunabai Laxman Nair
Charitable Hospital, Mumbai,
Maharashtra, India.

uddhaoz1@gmail.com

Received: 26 June 2024
Accepted: 03 December 2024
EPub Ahead of Print: 16 January 2025
Published:

DOI
10.25259/IJPGD_129_2024

Quick Response Code:



Dear Editor,

Hair loss in young children can present a challenging scenario for dermatologists to identify and manage. Physicians should always consider the possibility of a hereditary hair condition when assessing a patient. Taking a comprehensive history, including family history and performing an extensive physical examination of the hair using dermoscopy and biopsy can assist in reaching a diagnosis. Understanding the pathophysiology of genetic hair defects can lead to a better comprehension of treatment and prognosis.^[1]

We report a case of congenital alopecia, where the clinical and dermoscopic characteristics helped us confirm the diagnosis.

A 12-year-old boy presented with diffuse hair loss all over the body for 2 years of age. Hair was normal at birth; however, the patient lost hair at the age of 2 years followed by the development of tiny skin-coloured lesions on scalp. There was no family history of similar complaints. Clinical examination revealed multiple skin-coloured follicular papules on scalp, eyebrows, legs and arms with non-scarring universal alopecia [Figure 1]. There were few hair on scalp, approximately 10–15 in number, with positive hair pull test. Dermoscopy of the scalp revealed pigtail hair, coiled hair, non-erupted vellus hair and a single Monilethrix hair [Figure 2]. However, trichogram did not reveal any specific findings. Histopathology showed sparse superficial lymphohistiocytic infiltrate with increased number of arrector pili with normal number of follicles suggestive

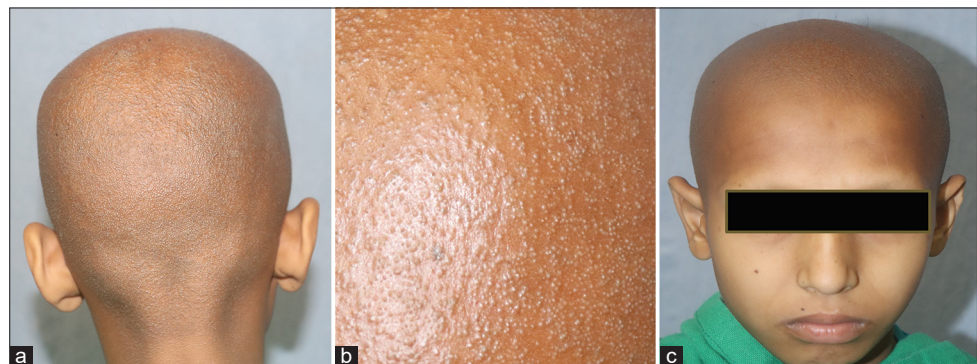

Figure 1: (a-b) Multiple skin-coloured follicular papules on scalp and (c) eyebrows with non-scarring universal alopecia.

This is an open-access article distributed under the terms of the Creative Commons Attribution-Non Commercial-Share Alike 4.0 License, which allows others to remix, transform, and build upon the work non-commercially, as long as the author is credited and the new creations are licensed under the identical terms.

©2025 Published by Scientific Scholar on behalf of Indian Journal of Postgraduate Dermatology

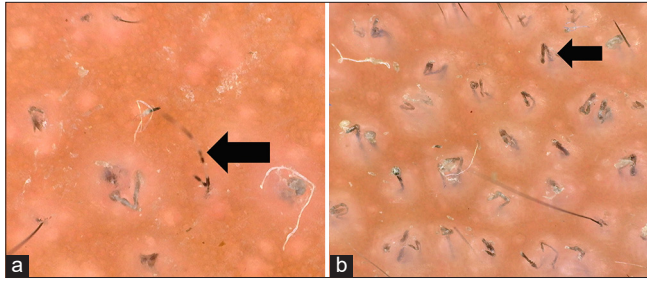


Figure 2: (a) Monilethrix hair (black arrow), (b) non-erupted vellus hair-pigtail hair (black arrow).

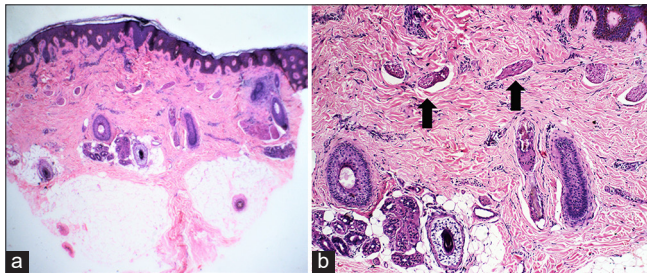


Figure 3: (a) Haematoxylin and eosin (H&E): ×40 and (b) H&E: ×100- Sparse superficial lymphohistiocytic infiltrate with increased number of arrector pili (black arrows) with normal number of follicles representing telogen-anagen units suggestive of non-scarring alopecia.

of non-scarring alopecia [Figure 3], thus confirming the diagnosis of Monilethrix-like congenital hypotrichosis. We did not perform any genetic studies due to non-affordability of the patient. We prescribed the patient topical minoxidil 2% solution to be applied once at night. The patient showed no improvement after 3-month follow-up. Monilethrix meaning ‘beaded hair’ comes from the Latin term ‘monile,’ meaning ‘necklace’ and the Greek word ‘thrix,’ which means ‘hair’. This condition is inherited in an autosomal-dominant manner. It exhibits a high penetrance rate, although its severity can range from mild to severe. Three genes (KRT81, KRT83 and KRT86) are linked to Monilethrix, as they code for type II hair keratins Hb1, Hb3 and Hb6. An autosomal recessive variant of Monilethrix is attributed to mutations in the DSG4 gene, which encodes the desmoglein 4 protein.^[2]

At birth, the scalp hair on the scalp typically appears normal; however, within weeks or months, it is replaced by dry, brittle hair that breaks off easily. The areas most commonly affected include the hair on the nape of the neck and the occipital region, often accompanied by follicular keratosis. However, the entire scalp was involved in our case, making this case distinctive.^[3]

Eyebrows, eyelashes and body hair can be affected, too. It can be associated with keratosis pilaris, koilonychia, retarded growth and juvenile cataract. However, an alternative diagnosis of generalised papular atrichia due to a HR gene mutation (hairless) should be considered. In that condition, hair loss occurs within a few months of life, and histopathological examination reveals

a complete absence of hair follicles.^[4] In contrast, our case showed a normal number of hair follicles on histopathology. In addition, we could not conduct genetic studies due to the patient’s financial constraints. Dermoscopy reveals normal medullated nodes in hair with non-medullated internodal thin hair at consistent intervals. The internode indicates the affected abnormal hair, which is easily fractured, indicative of Monilethrix hair. Monilethrix hair tends to persist into adulthood but may show improvement during pregnancy and puberty. A study investigated oral etretinate at a dose of 0.5 mg/kg/day and acitretin at the same dosage, yielding satisfactory results; however, a relapse occurred once the treatment was discontinued.^[5]

Ethical approval

Institutional Review Board approval is not required.

Declaration of patient consent

The authors certify that they have obtained all appropriate patient consent.

Financial support and sponsorship

Nil.

Conflicts of interest

There are no conflicts of interest.

Use of artificial intelligence (AI)-assisted technology for manuscript preparation

The authors confirm that there was no use of artificial intelligence (AI)-assisted technology for assisting in the writing or editing of the manuscript and no images were manipulated using AI.

REFERENCES

1. Ahmed A, Almohanna H, Griggs J, Tosti A. Genetic Hair Disorders: A Review. *Dermatol Ther (Heidelb)* 2019;9:421-48.
2. Oliveira EF, Araripe AL. Monilethrix: A Typical Case Report with Microscopic and Dermoscopic Findings. *An Bras Dermatol* 2015;90:126-7.
3. Narmatha GR, Chithra S, Balasubramanian N. Monilethrix. *Indian J Dermatol Venereol Leprol* 2002;68:220-1.
4. Massé M, Martinez-Mir A, Lam H, Geraghty MT, Christiano AM. Identification of a Recurrent Mutation in the Human Hairless Gene Underlying Atrichia with Papular Lesions. *Clin Exp Dermatol* 2005;30:363-5.
5. De Berker D, Dawber RP. Monilethrix Treated with Oral Retinoids. *Clin Exp Dermatol* 1991;16:226-8.

How to cite this article: Ghatbandhe VV, Zambare US, Dongre AM, Nayak C. Monilethrix-like Congenital Hypotrichosis: A Unique Hair Fragility Disorder. *Indian J Postgrad Dermatol*. doi: 10.25259/IJPGD_129_2024