

Clinicodermoscopic Challenge

Diascopy and Dermatoscopy of Lupus Vulgaris: The Tale of 'Apple-jelly' Nodules

Prakhar Srivastava¹, Prachi Srivastava², Niti Khunger¹

¹Department of Dermatology and STD, Vardhman Mahavir Medical College and Safdarjung Hospital, New Delhi, ²Department of Dermatology and STD, American International Institute of Medical Sciences and GBH Hospital, Udaipur, Rajasthan, India.

*Corresponding author:

Prakhar Srivastava,
Department of Dermatology
and STD, Vardhman Mahavir
Medical College and Safdarjung
Hospital, New Delhi, India.
sripakhar1996@gmail.com

Received: 16 September 2023
Accepted: 01 October 2023
Epub ahead of print: 22 November 2023
Published: 12 February 2024

DOI
[10.25259/IJPGD_88_2023](https://doi.org/10.25259/IJPGD_88_2023)

Quick Response Code:



CASE DESCRIPTION AND DERMATOSCOPIC FINDINGS

A lady in her 40s presented with a reddish lesion on the right side of her face of 6 months duration. On examination, solitary, succulent, and reddish-brown plaque measuring 10 × 6 cm was present over the lower right cheek, with scarring at the inferior margin and serpiginous progression at the superior margin [Figure 1]. Diascopy showed apple-jelly nodules, and dermatoscopy revealed yellow-brown areas with overlying branching vessels and white scales [Figures 2 and 3]. Mantoux test was strongly positive. Histopathology showed epithelioid granulomas.

DIAGNOSIS AND DISCUSSION

Cutaneous tuberculosis (TB) constitutes around 1% of extrapulmonary TB. Lupus vulgaris (LV), also called as tuberculosis cutis luposa or boeck's sarcoid, is a chronic, progressive, post-primary and paucibacillary form of cutaneous TB, occurring in a person with moderate to high

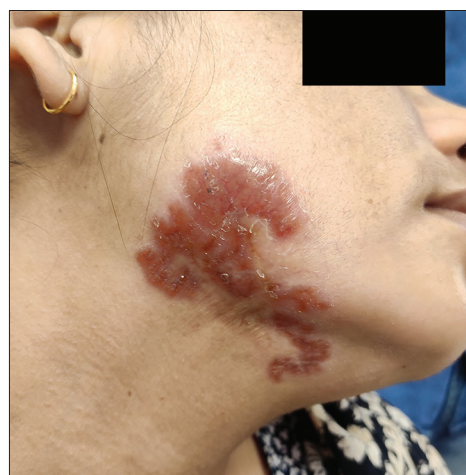

Figure 1: Solitary, reddish-brown plaque presents over the lower right cheek, with scarring at the inferior margin and serpiginous progression at the superior margin.

This is an open-access article distributed under the terms of the Creative Commons Attribution-Non Commercial-Share Alike 4.0 License, which allows others to remix, transform, and build upon the work non-commercially, as long as the author is credited and the new creations are licensed under the identical terms.

©2024 Published by Scientific Scholar on behalf of Indian Journal of Postgraduate Dermatology

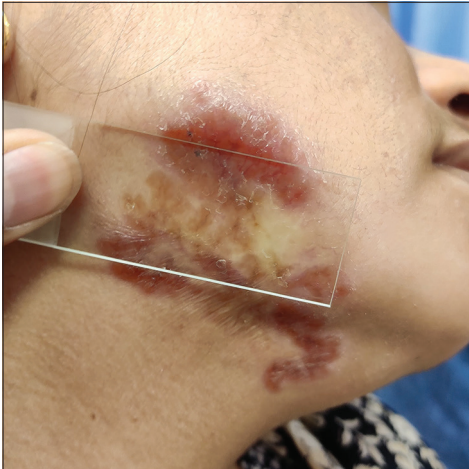

Figure 2: Diascopy showing apple-jelly nodules.

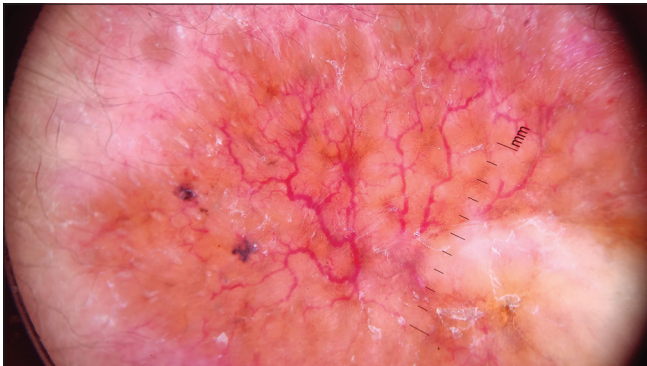


Figure 3: Dermatoscopy showing linear focussed telangiectasias on a yellow-brown background and white scales (DermLite DL3N; dry, contact, polarised, $\times 10$).

immunity. It can arise either from an endogenous underlying focus or through exogenous inoculation. In India, buttocks and extremities are commonly affected, while in the West, facial involvement is commoner. It presents as brownish to erythematous, soft and solitary plaque, having an advancing edge and a scarring edge. It has several clinical variants such as papular, nodular, plaque, vegetative, ulcerative, atrophic, hypertrophic, mutilating and tumour-like.^[1]

Lupoma is the characteristic dermatological lesion of LV. It can be well-demonstrated by diascopy or dermatoscopy, both of which show the 'apple jelly' or 'suere d'orge' (barley sugar) nodules.^[2] Dermatoscopy, an intermediate between macroscopic and microscopic dermatology, reveals linear focussed telangiectasias on a yellow-brown background.^[3] Yellow-brown areas are a hallmark of cutaneous granulomatous disorders, which include infectious granulomatous disorders, such as mycobacterial diseases, fungal diseases, leishmaniasis and syphilis, as well as non-infectious granulomatous disorders, such as sarcoidosis, necrobiotic disorders, interstitial granulomatous dermatitis, granulomatous rosacea and

foreign body granulomas. The yellow-brown appearance is attributed to the mass effect of dermal granulomas. Apart from granulomatous disorders, similar yellow-brown areas have also been reported due to dense dermal cellular infiltration, such as xanthogranuloma, lymphomas and pseudo-lymphomas. The granulomas of LV are more yellowish than sarcoidosis because of the occasional presence of caseous necrosis, which makes the granuloma less compact, as well as due to the lipid deposition within the multinucleate Langhans giant cells.^[3]

Jonathan Hutchinson first described the apple-jelly nodules. In 1865, he wrote, 'Patches of lupus often present a very peculiar tint; they are at parts glossy and semi-transparent. Mr. Wilson (Erasmus Wilson) has well compared them to 'reddish transparent jelly effused on the skin and streaked with the ramifications of a few small blood vessels.'^[4] The term apple-jelly nodule was used to describe the 'papules on plaque' or the 'tubers on plaque' appearance of LV, with yellow-brown papules or nodules at the margins of the lesion, reminiscent of apple-jelly.^[5] They have also been described as 'apple-butter nodules.'^[6] Linear or branching vessels seen on dermatoscopy signify the dilated dermal capillaries pushed up by the underlying granulomas. Other dermatoscopic features of LV include white structureless areas, white lines, follicular plugs, and scales.^[7]

Ethical approval

Institutional Review Board approval is not required.

Declaration of patient consent

The authors certify that they have obtained all appropriate patient consent.

Financial support and sponsorship

Nil.

Conflicts of interest

There are no conflicts of interest.

Use of artificial intelligence (AI)-assisted technology for manuscript preparation

The authors confirm that there was no use of artificial intelligence (AI)-assisted technology for assisting in the writing or editing of the manuscript and no images were manipulated using AI.

REFERENCES

1. Arora K, Batra A, Dhanta A, Hazarika N. Lupus Vulgaris in a Mother and Child. *BMJ Case Rep* 2021;14:e240591.
2. Gaumond E. Lupus Vulgaris and Vitamin D2. *Can Med Assoc*

- J 1948;59:522.
3. Chauhan P, Adya KA. Dermatoscopy of Cutaneous Granulomatous Disorders. *Indian Dermatol Online J* 2021; 12:34-44.
 4. Russell B. The History of Lupus Vulgaris: Its Recognition, Nature, Treatment and Prevention. In: Section of the History of Medicine. London: Proceedings of the Royal Society of Medicine; 1954. p. 127-8.
 5. Narayanan A, Dharanisankar S, Badhe BA, Ramassamy S. Apple-jelly Nodules of Cutaneous Rosai-Dorfman Disease. *Indian Dermatol Online J* 2023;14:419-21.
 6. Goldman L, Plotnick H, Balinkin I. Investigative and Clinical Studies with Diascopy in Dermatology. *AMA Arch Dermatol* 1957;75:699-705.
 7. Jindal R, Chauhan P, Sethi S. Dermoscopy of the Diverse Spectrum of Cutaneous Tuberculosis in the Skin of Color. *Dermatol Pract Concept* 2022;12:e2022203.

How to cite this article: Srivastava P, Srivastava P, Khunger N. Diascopy and Dermatoscopy of Lupus Vulgaris: The Tale of 'Apple-jelly' Nodules. *Indian J Postgrad Dermatol.* 2024;2:54-6. doi:10.25259/IJPGD_88_2023